

Research Article

Mast Cells Released Inflammatory Markers Play a Vital Role in Mandibular Remodeling of Odontogenic Keratocyst Patients

Zulaikha Malik¹, Armaghan Israr Mirza², Muhammad Adnan Akram³, Adnan Arshad⁴, Amber Kiyani⁵

^{1,4}K.A.M School of Life Sciences, Forman Christian College University, Lahore; ²Department of Oral and Maxillofacial Surgery, KEMU/ Mayo Hospital, Lahore; ³Department of Oral & Maxillofacial Surgery Azra Nabeed Medical College, Lahore; ⁵Department of Oral Pathology and Medicine, Riphah International University, Islamabad

Abstract:

Background: Odontogenic Keratocyst (OKC) falls among the distinctive and rare odontogenic developmental cyst which is derivative of the dental lamina and contains clear fluid along with a cheesy material which resembles keratin debris. Treatment strategies for OKC are for the most part classified as conservative or aggressive. Mast Cells play an important role in the pathogenesis of inflammatory conditions.

Objective: The goal of our study was to observe the participation of inflammatory mediators (RANKL, TNF- α , TGF- β and MMP-9) in the pathogenesis as well as the recovery process of OKC.

Methods: Enrolled patients were divided into three groups while a fourth group was formed of the control individuals. Sampling of all groups was done once after required data collection. Blood samples were taken, mRNA extraction and cDNA was then subjected to qRT-PCR. IHC for mast cells was done on patient samples.

Results: qRT-PCR showed higher expressions of inflammatory markers in patients undergoing treatment as compared to individuals with completed treatment procedure. Levels of RANKL were high in patients that were currently undergoing bone development as compared to other patients. The levels of TNF- α were comparatively higher in patients who showed visible signs of inflammation like swelling and pain. TGF- β and MMP-9 expression levels showed correlation with each other in all three groups. Both these cytokines were also found to be in association with mast cells. The results of histochemical staining of mast cells suggested the involvement of these cells in the pathogenesis of the cystic lesion via inflammation.

Conclusions: The findings of the study suggest that the expressions of inflammatory mediators correlate with the presence of mast cells, therefore, application of mast cells stabilizers in addition to marsupialization in the treatment of OKC can be a prospective treatment strategy in future clinical settings.

Corresponding Author | Dr. Adnan Arshad, Assistant Professor, KAM School of Life Sciences, Forman Christian College (A Chartered University), Lahore **Email:** adnanarshad@fccollege.edu.pk

Key Words: Odontogenic keratocyst, Mast cells, RANKL, TNF- α , TGF- β , MMP-9

Introduction:

Odontogenic Keratocyst (OKC) was the term coined by Philipsen in 1956. OKC is defined as: “odontogenic, benign uni or multicystic tumors which are intraosseous characterized by parakeratinized squamous epithelium lining and have a potential for infiltrative and aggressive growth”. OKC is named so as keratin is produced by the cystic lining. This cyst is an

intraosseous parakeratin lined lesion. Odontogenic Keratocyst (OKC) falls among the distinctive and rare odontogenic developmental cyst which is derivative of the dental lamina and contains clear fluid along with a cheesy material which resembles keratin debris. Vigorous growth in jaws, ability to invade anatomical structures present in vicinity and frequent malignant alterations are the characteristics which make OKC a

standout from other types of odontogenic cysts. Such set of pathological characteristics make OKC a standout amongst the most contemplated cystic lesions of jaw¹⁻⁴.

Considering the epidemiology, OKC accounts for approximately 7.8% cysts of the maxillofacial region and incidence is from 4-16.5%. They can occur in all age groups, and a peak incidence is in the second and fourth decades of life⁵. It occurs predominantly in whites with ratio of 1.6:1 in males and females. The peripheral OKC has predominance in females with male:female ratio of 2.2:1. Another astounding character of OKC is a significantly high rate of recurrence. Recurrence rates reported of OKC fall between 25% to 60%. Most recurrences occur within 5-7 years post treatment, although few recurrences were encountered after 10 years after initial surgery⁶⁻¹⁰. The mean recurrence time in males was upto 4 years and for females it was found to be 7 years. The variations in reported results can be a consequence of wide range of surgical techniques and varied duration of follow-up of patients. Recurrence rates of OKC are seen to reduce when more meticulous surgical treatment is done i.e. recurrence rate of 30% with enucleation, 33% with marsupialization and 38% with enucleation + cryotherapy had been reported by Madras and Lapointe¹¹⁻¹⁴.

Inflammatory cytokines involve a vital role in the cystic expansion. These include stimulation of cells resembling osteoclasts present in the capsule at the tips of intraosseous extension or synthesis of collagenases which are biologically active. A synergistic effect of both (osteoclasts and collagenases) may also initiate bone resorption. Elevated intracystic fluid pressure might also be involved in activation of growth of odontogenic cysts as it has been observed that pressure of fluid in odontogenic cysts is high as compared to atmospheric pressure^{15,16}.

Mast cells synthesize multiple pro-inflammatory cytokines and play an important role in the initiation of inflammatory responses. Bone loss is also regulated by mast cells as they play a part in the development of osteoporosis. It also has been reported that mast cells can fluctuate the activity of osteoclasts via the release of stem cell factor associated with granules. Mast cells can also encourage resorption of bone through production of heparin and synthesis of TNF- α , both factors initiate

osteoclastic activity. Association of mast cells with odontogenic tumors and cysts like PC, DC and OKC has also been speculated. Degranulation of mast cells secretes many factors that contribute significantly in cascades of proteolysis and also have impact on endothelial cells by initiating their proliferation and migration. Past researches have suggested that the products of mast cell degranulation can be correlated with elevation in extracellular matrix destruction in the wall of the cyst and also with production of cytokine, thus supporting the progression of these lesions^{17,18}.

Methods:

A total of 30 patients were included in this study after the approval from Ethical Review Committee of Forman Christian College University (ERC-37-2018). Patients showed no previous history of any oral pathology. Patients were divided into three groups: *Group 1*: 9 Patients at beginning of treatment procedure. *Group 2*: 9 Patients midway treatment procedure. *Group 3*: 12 Patients with completed treatment. 3 healthy individuals with no oral pathology were taken and placed into a separate group i.e. Control Group (n=3).

RT-qPCR Analysis

Primers were designed against RANKL, TNF- α , TGF- β , MMP-9 and GAPDH (internal positive control).

Forward 3'-TCTATGGTCCTCGCCCTGAA-5'

Reverse 3'-CATCGTCCACCGGACTCAA-5'

TNF- α Forward 3'-

CACAGTGAAGTGCTGGCAAC-5'

Reverse 3'-AGGAAGGCCTAAGGTCCACT-5'

TGF- β Forward 3'-

GTGGACATCAACGGGTTTAC-5'

Reverse 3'-GAGGTCCTTGCGGAAGTCAA-5'

RANKL Forward 3'-

CCGCCTAAGTGGAGATAAGGAAAT-5'

Reverse 3'-CGTTCCCCGCGAAGGAG-5'

Blood sample from patients was taken and RNA was extracted using TRIzolTM Reagent (by Thermo-fisher, catalogue no. 15596026). Single stranded cDNA synthesis was done by using Reverse Transcriptase Kit, Thermo Scientific Catalogue # K1622. Procedure followed to make cDNA was mentioned in manufacturer's transcript. The cDNA was then stored at -20°C till fur-

ther analysis. The RT-qPCR was performed on Rotor-Gene Q (Machine Serial No. 1116194) by Qiagen for measuring the expression levels of mRNA of the inflammatory markers RANKL, TGF- β , TNF- α and MMP 9. For quantification SybrGreen Master Mix 2x (Thermo Scientific, Catalogue # K0221) was used. Livak's method⁷ was used for the analysis of data obtained from RT-PCR by analyzing the difference in fold of expression of all inflammatory markers. Relative expressions of markers were calculated with reference to controls by applying the following formula:

$$\Delta Ct (\text{sample}) = (Ct \text{ target} - Ct \text{ reference})$$

$$\Delta Ct (\text{calibrator}) = (Ct \text{ target} - Ct \text{ reference})$$

$$\Delta\Delta Ct = \Delta Ct \text{ calibrator} - \Delta Ct \text{ experimental}$$

$$\text{Fold increase} = 2^{-\Delta\Delta Ct}$$

Fold increase of markers is then calculated by taking $\Delta\Delta Ct$ exponent of 2. This fold increase was subjected to comparative analysis and graphs were plotted.

Quantification of Mast Cells:

Biopsy blocks of patients were obtained from Shaukat Khanum Memorial Hospital and Agha Khan University Hospital collection centers. Hemotoxylin and eosin slides were viewed under a light microscope to identify mast cells. The number of total mast cells was calculated with the assistance of a counter. Additional sections were created from the paraffin blocks. These sections were deparaffinized and hydrated. They were stained with toluidine blue. Following multiple washings, the sections were dipped in alcohol, xylene and cover slipped. The mast cells stained red. The number of mast cells was confirmed on these sections.

Results:

Patients Demography and Clinical Feature

A total of 30 patients (10 males and 20 females) were included in this study. The average age of males was 32.5 ± 16.6 years while that of females was 18 ± 4.8 years. Patients showed no previous history of any oral pathology like delayed teeth eruption, tooth decay (cavities), fractured teeth, gum disease, tooth sores, teeth sensitivity, difficulty in chewing etc. The characteristic presenting symptom found in all patients was anterior mandibular swelling on left or right side (Figure 1 A and Table 1) Majority of patients showed no pain at the site of lesion. X-Ray findings of the patients peri-coronal

Figure Legends

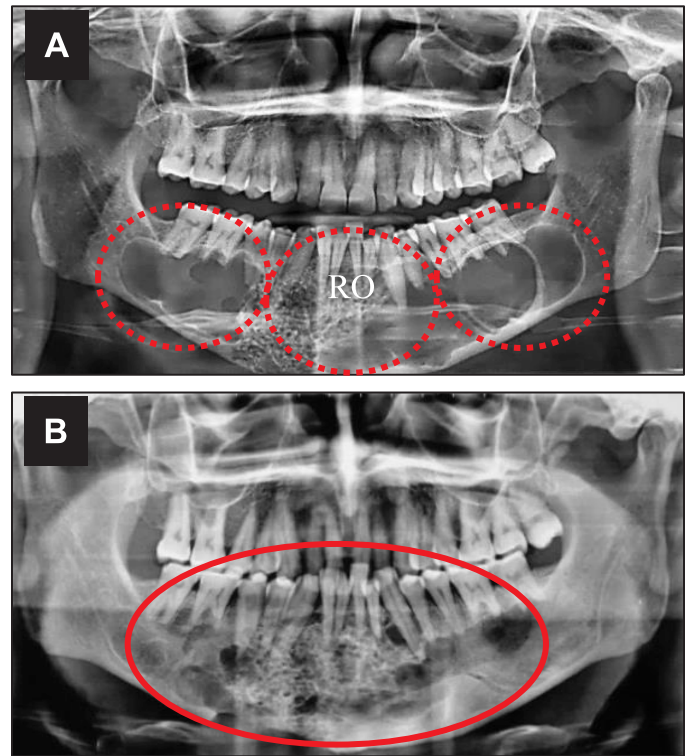


Figure 1: A) Multilocular heterogenous radiolucencies including whole of mandibular corpus from right to left angle of mandible. Anterior mandible contains a patchy radio-opacity. B) Resolved radiolucencies in both right and left posterior mandibles with no change in radio-opacity (RO).

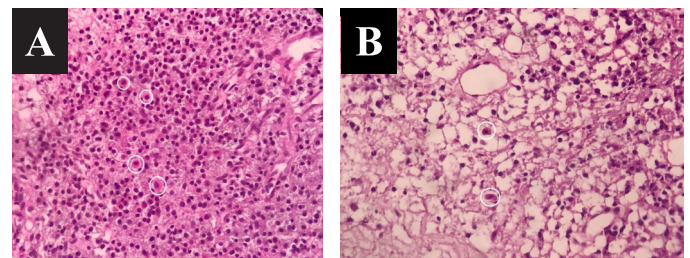


Figure 2: Mast cell quantification. A) Diffused mast cells present in OKC from patient 2.2 (20X resolution). B). Solitary mast cell clusters in OKC from patient 1.3 (20X resolution)

radiolucent lesions with displaced wisdom teeth and ill-defined radiolucent lesion in left or right ramus.

Histological Features of OKC in different Groups:

Biopsy reports of all patients indicated characteristic features of OKC which included cyst lined by squamous epithelium showing palisaded hyperchromatic cells and focal parakeratosis, fibroconnective & fibrocollagenous tissue, surface corrugation and inflammation. Surrounding areas showed moderate inflammatory infiltrates. No signs of malignancy were observed.

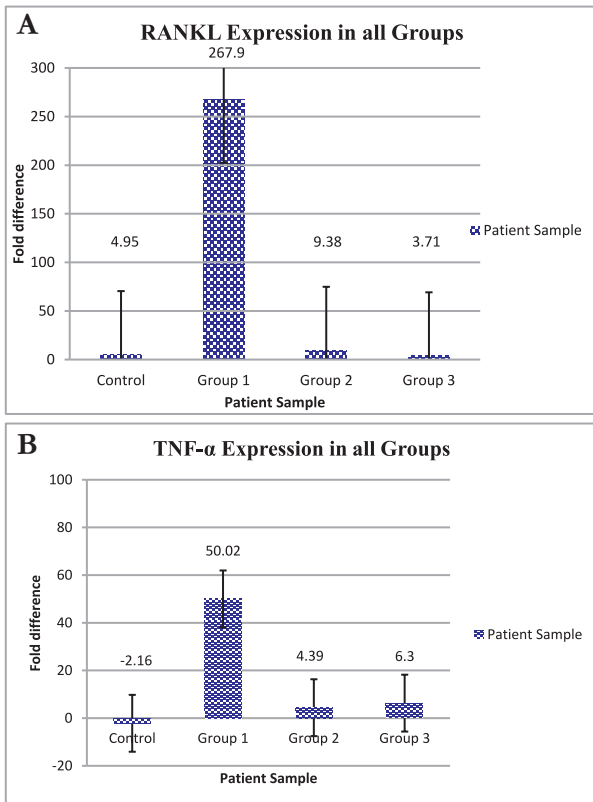


Figure 3: Expression of RANKL & TNF- α in all groups. Errors bars represent Standard Error (SE) of the mean estimated.

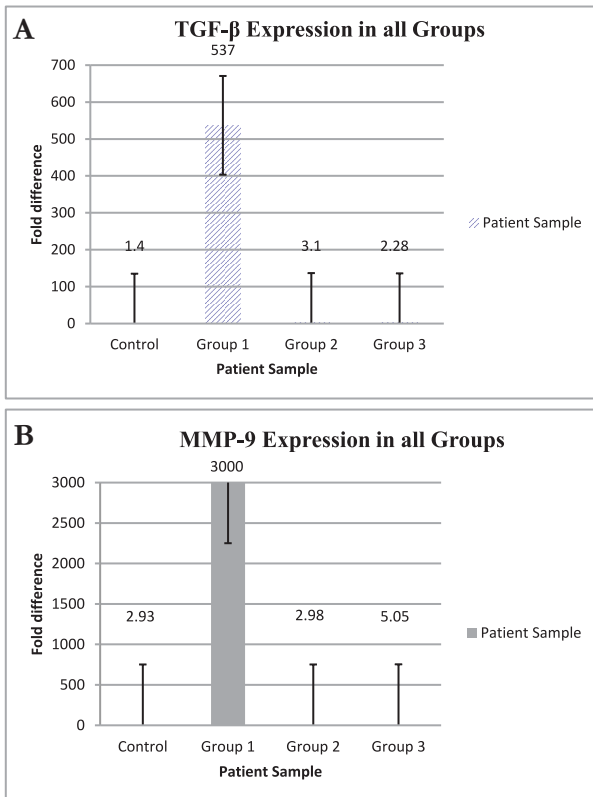


Figure 4: Expression of TGF- β & MMP-9 in all groups. Errors bars represent Standard Error (SE) of the mean estimated.

Table 1: Summary of the clinical features of enrolled patients.

Group	Patient ID.	Gender	Location
Group CTRL	3 Individuals with no oral pathology were included as controls		
Group 1	1.1, 1.2,	F	Mandible
	1.4,1.5		
Group 2	1.3,	M	Mandible & Ramus
	1.6,1.7,1.8,1.9		
	2.1, 2.2, 2.7	M	Maxilla
Group 3	2.3, 2.4,	F	Mandible
	2.8,2.9		
	3.2	F	Ramus
	3.3,3.5, 3.6, 3.7,	M	Mandible
	3.12		
	3.4, 3.8, 3.10	F	Mandible
	3.1, 3.9, 3.11,	F	Mandible, Maxilla & Ramus

Table 2: Mast Cell Quantification

Sr. no.	Pt. Group	No. of mast cells	Other findings
1.	3	Zero mast cells	Sprinkling of inflammatory cells. One large focus perivascular inflammation. Multiple foci of inflammation, primarily subepithelial, hemorrhage noted.
2.	2	6-8 mast cells	Scattered, deep and subepithelial infiltrates.
		188 mast cells	Diffused distribution in deep infiltrates
3.	1	2-4 mast cells	Mast cells at periphery of deep infiltrates. Multiple foci of inflammation, chronic inflammatory cells.

RANKL correlates directly with Osteogenesis:

Quantification of RANKL in all groups suggest that in patients undergoing treatment level of RANKL is high as compared to patients who have their treatment procedures completed. (Fig. 3). X-ray findings of patients of group 1 and 2 reveal that patients undergoing osteoclastogenesis had high expression of RANKL whereas in patients where bone growth was not significant due to completion of treatment, expression of RANKL was low (Figure 1A)

Inflammatory mediator TNF- increases during Inflammation:

Highest expression of TNF- α was seen in group 2 where patients had clinical swelling (Figure 1 B). Patients with completed treatment (Group 3) also indicate high levels of TNF- α as compared to control. This can be a consequence of secondary healing which increases with the passage of time. (Figure 3)

TGF- β and MMP-9 level increases during bone healing:

The pattern of change in expression of TGF- β and MMP-9 was similar to each other. Elevation in expression level of TGF- β and MMP-9 increased during the early healing period was observed in a patient of Group 1. The level was significantly less or equal to control in other patients as they still have lesion present in the mandibular region (Group 1) or patients having bone formation completed. (Figure 4).

Mast Cell Quantification in different Groups:

No mast cells were observed in patients of Group 3 although foci of inflammation were seen. Patient from group 1 showed mast cells along with multiple foci of inflammation. Highest number of mast cells was seen in patient from group 2 with diffused distribution in deep infiltrates as shown in Table 2 and Figure 2.

Discussion:

The results showed that during the phase of healing and formation of bone, patients showed high expression of inflammatory markers while patients with treatment completed had their levels close to normal (as observed in control persons). This variation can be understood in a better way by the fact that cystic/tumor cells release elements that cause activation of osteoblast and formation of bone. RANKL is released by osteoblasts along

with other factors that further activate osteoclasts leading to resorption of bones. As a consequence, growth factors (TGF- β) that trigger growth and maintenance of tumors are released. The change in balance between bone formation and resorption is due to the continuous change in the concentrations of these elements^{2,3}.

Differentiation and activation of pro-osteoclasts (osteoclast precursor cells) to mature (active) osteoclasts requires binding of RANKL to RANK. RANKL, which is expressed in cells such as osteoblasts, promotes osteoclast differentiation through signals from receptors expressed by osteoclast precursors. The patients enrolled in the study have shown high levels of RANKL than normal (control). This can be explained by the fact that RANKL is an osteoclastogenesis induction factor and is involved in all bone resorption diseases regardless of inflammation or tumor induction¹⁶. The patients undergoing treatment showed significantly high levels of RANKL which is comparable with their x-ray findings, thus, proving the contribution of RANKL in bone remodeling. The patients post treatment showed relatively low levels than controls.

Stimulation of osteoclastogenesis and inhibition of osteoblast function is the classical role performed by TNF- α in regulating homeostasis of bone. The patients included in our study showed detectable levels of TNF- α that were not much high as compared to the normal individuals with exceptions of a few patients. The highest expression of TNF- α was observed in patient 1.2. The patient had increased swelling at the site of lesion.

The presence of TNF- α , TGF- β and MMP-9 can be correlated with role of mast cells in OKC, Mast cells themselves turn on their metabolism during the inflammation processes and large amounts of inflammatory mediators are quickly released. Mast cells can act in the pathogenesis of OKC in multiple ways. Degranulation of mast cells causes release of a variety of hydrolytic enzymes. These enzymes are expected to hydrolyze components of the connective tissue capsule of odontogenic cysts. The diffusion of these components into the luminal fluid due to poor lymphatic drainage will contribute towards the increase in osmotic pressure of the cyst. It has also been suggested that collagenolytic activity is promoted by mast cells. As activity of colla-

genes has been reported in odontogenic cysts so the pathogenesis of OKC can be correlated with the presence of mast cells. Eosinophils chemoattractant factor (ECF) and histamine are released by mast cells. These attract the eosinophils present in tissues and have been suggested in initiating the production of prostaglandins. These prostaglandins are of significance in bone resorption for the growth of odontogenic cyst^{19,20}.

Fluctuations in the expression of inflammatory markers during the course of treatment suggest a positive conclusion for the presented hypothesis i.e. the increase and decrease of these markers leads to osteogenesis. In addition, the presence of mast cells can be a contributory factor in the pathogenesis of OKC as these mast cells release TGF- β and MMP-9, both of which had a co-joint expression in all groups under study. Furthermore, apart from traditional marsupialization and enucleation for treatment of OKC, mast cell stabilizers can be used due to their anti-inflammatory properties. It can not only accelerate the healing process but can also prevent recurrence.

Our study has some constraints which can be addressed in subsequent studies. Patients were reluctant of giving tissue samples during treatment, hence, we relied on blood sampling for quantification. Tissue samples would have provided a more clear picture of the pathogenesis at the site of cyst. The study can be extended with increase in sample size and duration. More number of patients can further validate the results and provide a more generalized pattern of inflammatory markers. Patient sampling can be done from the beginning till end at definite time intervals to see the change in expression levels at specific time periods. In addition to tissue samples, cystic secretions from the patients can also be collected which can be an additional information regarding cystic pressure and decompression during treatment.

Conclusions:

The findings of the study suggest that the expressions of inflammatory mediators correlate with the presence of mast cells, therefore, application of mast cells stabilizers in addition to marsupialization in the treatment of OKC can be a prospective treatment strategy in future clinical settings.

Ethical Approval: Given

Conflict of Interest: The authors declare no conflict of interest.

Funding Source: None

References:

1. Passi D, Singhal D, Singh M, Mishra V, Panwar Y. Odontogenic Keratocyst (OKC) or Keratocystic odontogenic tumor (KCOT)- Journey of OKC from cyst to tumor to cyst again; comprehensive review with recent updates on WHO classification. *Int J Curr Res.* 2017;9(7):54080-6.
2. Ahlfors E, Larsson A, Sjögren S. The odontogenic keratocyst: a benign cystic tumor? *J Oral Maxillofac Surg.* 1984;42(1):10-9.
3. Donoff RB, Harper E, Guralnick WC. Collagenolytic activity in keratocysts. *J Oral Surg.* 1972;30(12):879-84.
4. Lombardi T, Odell EW, Morgan PR. p53 immunohistochemistry of odontogenic keratocysts in relation to recurrence, basal-cell budding and basal-cell naevus syndrome. *Arch Oral Biol.* 1995;40(12):1081-4.
5. Chirapathomsakul D, Sastravaha P, Jansisyanont P. A review of odontogenic keratocysts and the behavior of recurrences. *Oral Surg Oral Med Oral Pathol Oral Radiol Endod.* 2006;101(1):5-9.
6. Zhao YF, Wei JX, Wang SP. Treatment of odontogenic keratocysts: a follow-up of 255 Chinese patients. *Oral Surg Oral Med Oral Pathol Oral Radiol Endod.* 2002;94(2):151-6.
7. Jo HJ, Kim HY, Kang DC, Leem DH, Baek JA, Ko SO. A clinical study of inferior alveolar nerve damage caused by Carnoy's solution used as a complementary therapeutic agent in a cystic lesion. *Maxillofac Plast Reconstr Surg.* 2020;42(1):16.
8. Bataineh AB, al Qudah M. Treatment of mandibular odontogenic keratocysts. *Oral Surg Oral Med Oral Pathol Oral Radiol Endod.* 1998;86(1):42-7.
9. Al-Moraissi EA, Dahan AA, Alwadeai MS, Oginni FO, Al-Jamali JM, Alkhatari AS, et al. What surgical treatment has the lowest recurrence rate following the management of keratocystic odontogenic tumor? A large systematic review and meta-analysis.

- J Cranio maxillo fac Surg. 2017;45(1):131-144.
10. Hu S, Li CM, Zhang SY, Qin S, Xie CL, Niu ZX, et al. Clinical value of oral repair membrane and β -tricalcium phosphate in the treatment of the postoperative bone defect of jaw cyst. *Hua Xi Kou Qiang Yi Xue Za Zhi*. 2020;38(5):541-545.
 11. Madras J, Lapointe H. Keratocystic odontogenic tumour: reclassification of the odontogenic keratocyst from cyst to tumour. *J Can Dent Assoc*. 2008;74(2):165-169.
 12. Abdoola I, Munzhelele IT, Ibrahim M. Extensive Mandibular Odontogenic Keratocysts associated with Basal Cell Nevus Syndrome Treated with Carnoy's Solution versus Marsupialization. *Ann Maxillofac Surg*. 2020;10(1):47-50.
 13. Tabrizi R, Hosseini Kordkheili MR, Jafarian M, Aghdashi F. Decompression or Marsupialization; Which Conservative Treatment is Associated with Low Recurrence Rate in Keratocystic Odontogenic Tumors? A Systematic Review. *J Dent (Shiraz)*. 2019;20(3):145-151.
 14. Prashanth BR, Vidhya MS, Karale R, Kumar GV. Is odontogenic keratocyst an endodontic enigma? A rare case report of management of odontogenic keratocyst in anterior mandible. *J Oral Maxillofac Pathol*. 2020;24(Suppl 1):7-10.
 15. Kubota Y, Yamashiro T, Oka S, Ninomiya T. Relation between size of odontogenic jaw cysts and the pressure of fluid within. *Br J Oral Maxillofac Surg*. 2004;42(6):391-395.
 16. Yamada C, Aikawa T, Okuno E, Miyagawa K, Amano K, Takahata S, et al. TGF- β in jaw tumor fluids induces RANKL expression in stromal fibroblasts. *Int J Oncol*. 2016;49(2):499-508.
 17. Džazić R, Sopta J, Minić AJ. Mast cells in periapical lesions: potential role in their pathogenesis. *J Oral Pathol Med*. 2010;39(3):257-62.
 18. Pinheiro JC, de Carvalho CHP, Galvão HC, Pereira Pinto L, de Souza LB, de Andrade Santos PP. Relationship between mast cells and E-cadherin in odontogenic keratocysts and radicular cysts. *Clin Oral Investig*. 2020;24(1):181-191.
 19. Livark K, Schmittgen T. Analysis of relative gene expression data using real-time quantitative PCR and the $2^{-\Delta\Delta C_T}$ method. *Methods*. 2001;25(3):402-408.
 20. Debta P, Debta FM, Chaudhary M, Wadhwan V. Evaluation of Infiltration of Immunological Cells (Tissue Eosinophil and Mast Cell) in Odontogenic Cysts by Using Special Stains. *J Clin Cell Immunol*. 2010;1(1):1000103.